

TO DETERMINE THE DISTAL RADIAL FRACTURE COMPLICATIONS FOLLOWING PLATE OESTEOSYNTHESIS USING DIFFERENT PLATES

Ashok Vidyarthi¹, Ashish Sirsikar², Sparsh Naik³, Tushar Sharma⁴, Jagmohan Singh Dhakar⁵

Received : 02/04/2023
Received in revised form : 30/04/2023
Accepted : 11/05/2023

Keywords:

Distal radial fracture complications, Plate osteosynthesis, Modified Henry's approach, Median Nerve Entrapment.

Corresponding Author:

Dr. Tushar Sharma,
Email: sharmatushar274@gmail.com

DOI: 10.47009/jamp.2023.5.3.212

Source of Support: Nil,
Conflict of Interest: None declared

Int J Acad Med Pharm
2023; 5 (3); 1036-1041



¹Professor & Head, Department of Orthopaedics, NSCB Medical College, Jabalpur, India

²Associate Professor, Department of Orthopaedics, NSCB Medical College, Jabalpur, India

³Assistant Professor, Department of Orthopaedics, NSCB Medical College, Jabalpur, India

⁴Post Graduate Resident, Department of Orthopaedics, NSCB Medical College, Jabalpur, India

⁵Statistician, Department of Community Medicine, NSCB Medical College, Jabalpur, India.

Abstract

Background: Distal radius fractures (DRF) are the most common orthopaedic injuries of the upper extremity. Patients with fracture of distal end of radius frequently have many complications and failure in the management may cause permanent disability. Therefore, this study aimed to find out the complications following plate osteosynthesis of distal radius fractures using different approaches. **Materials and Methods:** A Prospective study was conducted in Orthopaedic department at NSCB Medical College, Jabalpur with the sample size of 46. All the patients treated with plate osteosynthesis from the duration of 01 January 2021 to 31 June 2022, that met inclusion/excision criteria, were included in this study and followed up at 1, 3 and 6 months, respectively. Data analysis was done through IBM software SPSS version 23.0. **Results:** Current study presents predominance of male (61%), with age group of 30-40 years (46%). Among 46 patients, 17% of them developed complications, most commonly CRPS, followed by Median Nerve Entrapment under Surgical Scar, Dorsal Tendon Attrition, and Superficial We concluded that prevention of the possible complications that can occur following treatment of a distal radius fracture must be the surgeon's foremost concern. Complications that do arise should be treated sooner to prevent any further long-term consequences. However, plate osteosynthesis provides successful results for the treatment of both extra articular and intra articular unstable fractures of distal radius.

INTRODUCTION

Distal radius fractures (DRF) are the most common orthopaedic injuries of the upper extremity.^[1-2] It mostly occurs in the middle aged and elderly women, but also occurs in young men with high velocity injury. Distal end fractures crush the mechanical foundation of the man's most elegant tool, the hand and the grip. Patients with fracture of distal end of radius frequently have many complications and failure in the management may cause permanent disability. The most commonly outlined complications are nerve related, tendon related, and hardware related. However, Carpal tunnel syndrome is the most common nerve-related complication, although this more commonly occurs with distal radius fracture regardless of treatment modality.^[3] Vulnerable tendons with volar locking plates including both extensor tendons (extensor pollicis longus, extensor digitorum communis, extensor indicis) and flexor tendons (flexor pollicis

longus, flexor digitorum profundus), stood at a lower rate compared with dorsal plates.^[4-7]

Nevertheless, despite the high incidence, there is still no consensus regarding the adequate treatment strategy. Common treatment options currently include closed reduction, closed reduction with percutaneous pinning, intramedullary fixation, external fixation, and various open reduction and internal fixation strategies.^[8-11] Instead of the various available treatment modalities, open reduction and internal fixation with dorsal and volar plates usage has shown a steady increase in recent years due to faster functional recovery and also improved radiographic alignment.^[8,12-13] Moreover, the patients can be mobilized early and thereby, reduce the incidence of wrist stiffness. Difficulties with dorsal fixed-angle plates prompted the use of volar fixed-angle plates for dorsal fractures. Therefore, this study aimed to find out the complications following plate osteosynthesis of distal radius fractures using different approaches/implants.

MATERIALS AND METHODS

Institutional review board and Institutional Ethical approval was obtained for this prospective follow-up study. All patients treated with plate osteosynthesis from the duration of 01 January 2021 to 31 June 2022, that met inclusion/excision criteria, were included in this study and followed up at 1, 3 and 6 months at Department of Orthopaedics, N.S.C.B. Medical College & Hospital, Jabalpur (M.P.). Written informed consent was obtained from all the participating patients. They were treated exclusively at NSCB Medical College and Hospital, Jabalpur.

Indications for surgery included a displaced DRF with a dorsal tilt of more than 15 degrees, an intra-articular step of more than 1 mm, a radial shortening of more than 2 mm or an incongruity in the distal radioulnar joint in the standard radiographs.

Inclusion Criteria Stipulated

1. Patients (aged between 18 years and 55 years).
2. Comminuted or intra articular and extra articular fractures of distal end radius.

Exclusion Criteria Included

1. Patients aged below 18 years.
2. Patients medically unfit for surgery.
3. Pathological fractures.
4. Compound fractures.
5. Patients who are not willing for surgery.
6. Trauma cases > 4 weeks.

From the period of 2021 to 2022, a total of 46 patients were stabilized by plate osteosynthesis. Of these, 34 patients were stabilised with volar plating, 8 patients with dorsal plating and 4 with dual plating. Out of 46 patients, 40 were followed up for 24 weeks and 6 patients were lost 4 at 8th week and 2 at 12th week. Therefore, the final analysis totalled 40 patients.

Surgical Procedure

All procedures were performed using either general or regional anaesthesia in a supine position, under fluoroscopic assistance and a pneumatic arm tourniquet of 250 mmHg. A standard Modified Henry's approach was used for volar plating and dorsal approach used for dorsal plating. The fracture was reduced under image intensification and when necessary, temporarily fixed with K-wires. The plate was placed and initially fixed with a bicortical screw through the gliding hole. After ensuring exact positioning of the plate under image intensifier, the remaining plate holes were filled with angular stable screws. Care was taken that the screws at the articular surface were placed sub-chondrally to prevent dorsal protrusion. Screw length was taken 2 mm shorter to prevent protrusion. Routine antibiotics and anti-inflammatory drugs were given. Check x-ray were taken on 3rd postoperative day after Check Dress 1. Sterile dressings were done on 3rd and 5th postoperative day. Sutures were removed on 10th to 15th post operative day and

patient were discharged with below elbow pop slab. Patients were assessed clinically and radiographically at 1, 3 and 6 months to assess the fracture union and the progress of patient's recovery were documented. All patients started hand therapy of the free joints (shoulder, elbow, fingers) for both upper extremities on the first postoperative day. After slab removal on 12th day the wrist was then included in physiotherapy programme.

Outcome Evaluation

Outcome evaluation each of the patients, who returned for the follow-up investigation, underwent a standard X-ray of the wrist in two planes (anteroposterior and lateral). Range of motion (ROM) was measured in palmar flexion, dorsi flexion, supination, pronation, radial- and ulnar deviation at the follow-up investigation. Demographic data included age, gender, injured hand, mode of injury and interval between surgery and follow-up. Additionally, functional outcome analysed with Modified Mayo score and Demerit Point System of Gartland and Werley, grip strength by dynamometer were analysed.

All the intraoperative and postoperative complications that were documented in the surgical write ups were recorded and each return evaluation was analysed for complication. Complex regional pain syndrome (CRPS) was diagnosed clinically on the basis of the Veldman's criteria [14-15]. Frequency and causes of complications were analysed.

Radiological Reviews

The primary (pre-reduction), immediate postoperative as well as final radiographs were checked for alignment and intra-articular step-off. The fractures were classified according to the Frykman classification. An acceptable reduction was defined as 10 degrees of dorsal tilt, 15 degrees in radial inclination, 2 mm ulnar variance and 2 mm of articular incongruity.^[16-17] In the anteroposterior radiographs, radial inclination and radial length and in the lateral radiographs, the palmar tilt was measured. Fracture healing was defined as bony bridging of the radial, ulnar, and dorsal cortical aspects of the distal part of the radius.^[16,18] The lateral X-ray verified the plate position and was subsequently classified according to Soong et al. in Grade 0, I and II.^[19]

Ethical Permission

The study was conducted after getting ethical permission taken from the IEC committee of the medical college. Also, the written informed consent from the patients were taken prior to enrolling them for the study.

Statistical Analysis

The statistical analysis was performed by using IBM software SPSS 2version 3.0 (Statistical Package for Social Sciences). Descriptive statistics were performed to all study variables and Continuous variables are described as mean and standard deviation. Categorical variables were taken as frequency and percentage and detailed as graphs,

bar charts and pie charts. To compare scaled parameters Paired t test was used. Chi-square was used for testing categorical data. If p value <0.05, data was considered significant at 5% level of

significance and if p value ≤ 0.01 , it was considered highly significant at 1% level of significance.

RESULTS

Table 1: Distribution of study participants according to Sex (n=46)

Gender	Frequency	Percent
Male	28	60.9
Female	18	39.1
Total	46	100.0

A total of 46 cases shown in table No 1, patients aged between 18-55 years (mean \pm SD age of 34.71 ± 6.80) sustained fractures of lower end of radius. Distal radius fractures are more in males compared to females.

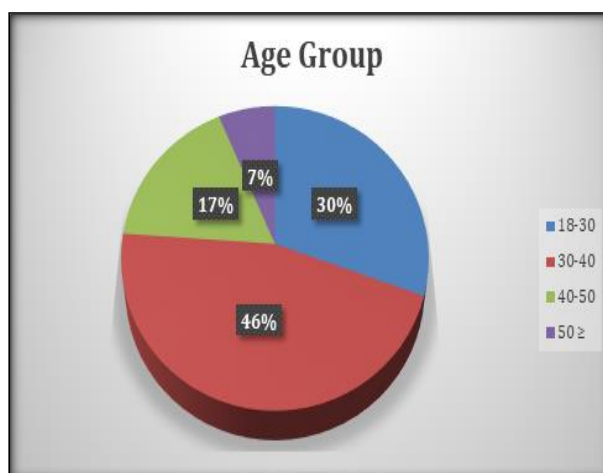


Figure 1: Distribution of study participants according to Age-group (n=46)

Above figure concluded that maximum number of cases i.e., 45.7% (n=21) were seen in the age group from 30-40 years, followed by 30% in 18-30 years (n=14), 17% seen in 40-50 years (n=8), and 7% in ≥ 50 (n=3).

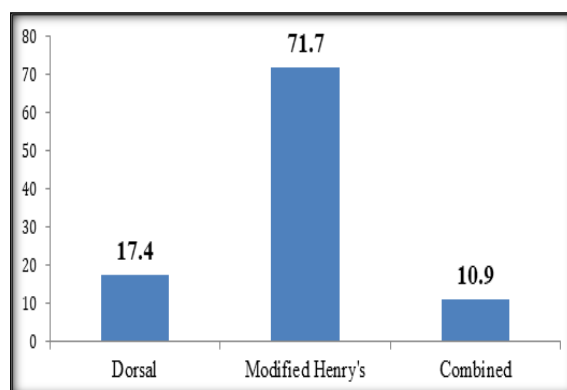


Figure 2: Distribution of Approaches used for patient's treatment

In Figure 2, in around 71.7% (n=33) of the patients Modified Henry's approach, however, in 17.4% (n=8) patient's dorsal approach was used, and in 10.9% (n=5) patients we used both the approaches.

Table 2: Distribution of the Complications reported by the patients

Complications	N	%
CRPS	4	8.7
Median Nerve Entrapment under Surgical Scar	1	2.2
Dorsal Tendon Attrition	1	2.2
Superficial Wound Infection	2	4.3
No Complication	38	82.6
Total	46	100.0

Out of the total of 46 patients, only 17.4% (n=8) of the patients developed complications. Among them 4 patients developed CRPS, 1 patient developed Median Nerve Entrapment under Surgical Scar, 1 patient developed Dorsal Tendon Attrition, 2 patients developed Superficial Wound Infection, while 83% (n=38) of the patients had no complications.

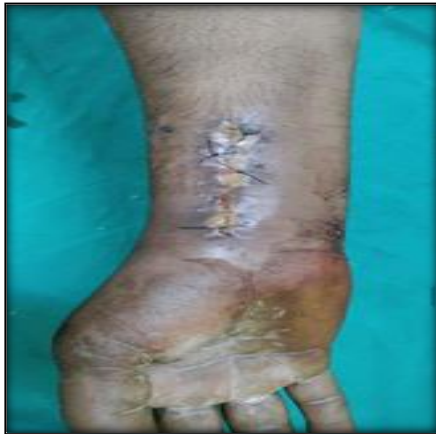

Figure 1: Superficial Wound Infection

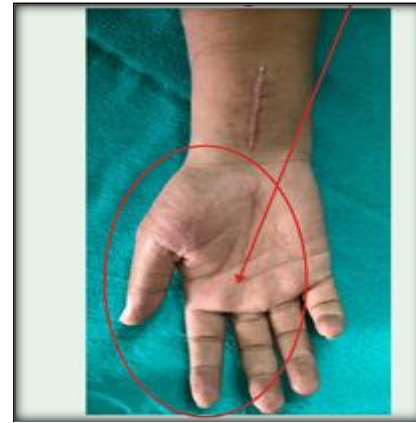


Figure 3: Sensory loss over lateral 3 1/2 finger




Figure 2: NCV median nerve sensory studies showed absent action potential

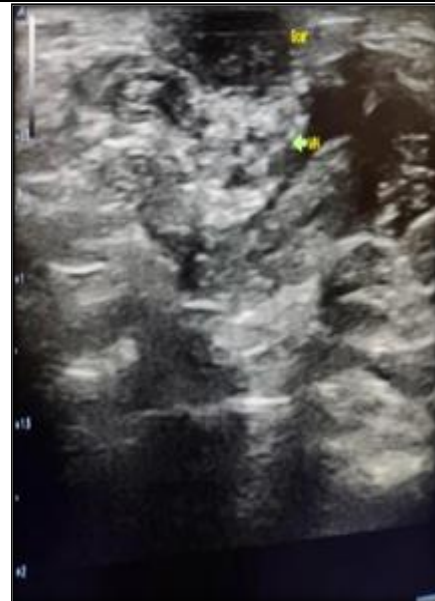


Figure 4: USG showing median nerve entrapped under scar

Table 3: Correlation of the complications and different Plates

Complication	Dorsal plating	Volar Plating	Combined	Total	p value
No Complication	6(15.8)	28(73.7)	4(10.5)	38	0.262
CRPS	2(50.0)	2(50.0)	0	4	
Median nerve entrapment under surgical scar	0	1	0	1	
Dorsal tendon attrition	0	0	1	1	
Superficial wound infection	0	2	0	2	
Total	8(17.4)	33(71.7)	5(10.9)	46	

Out of the 4 patients who developed CRPS, 50% of each had undergone Dorsal approach and Modified Henry's approach. In Median nerve entrapment under Surgical scar, single patient underwent Modified Henry's approach, while in Dorsal tendon attrition single patient underwent both Dorsal and Modified Henry's approach, and in Superficial wound infection, 2 patients underwent Modified Henry's approach. However no statistically significant association been found between complications and the plates being used for the treatment ($p < 0.05$).

DISCUSSION

Distal radius fractures are the most frequently seen upper extremity fractures. The primary goal in treatment of this injury is to provide good reduction and immediate stability to achieve anatomic fracture union, allow the quick return of hand function, and avoid complications.

Our study had a male preponderance with 28 male patients and 18 female patients. This can be attributed to the working group of population in which males are predominant working group. Yukichi zenke et al.^[20] reported female preponderance in both conventional and surgical groups akin to which can be explained due to the higher incidence of osteoporosis in females as the age increases. Similar results have been reported by

Tamara D et al.^[21] with female preponderance in their study. In another study by Marco Rizzo. Brain A. Katt. Joshua T.^[22] showed female preponderance while they were treating distal radius fractures treated with plate osteosynthesis. In a randomised prospective trial K. Egol et al.^[23] reported equal male to female distribution in both external fixation and plating group 50% and 57% respectively. Rohit Arora et al.^[24] in their prospective randomised trial comparing non operative treatment with volar locking plate fixation for displaced unstable distal radius fractures in patients 65years and older reported a female preponderance. In study by Kilic A et al.^[25] who reported male preponderance with male to female ratio of 1.25:1.

In present study, the age group ranged from >18years to 55 years with mean age of 34.71 ± 6.80 . In our study, distal radius fracture was more common in age group of 31 to 40 years old and were related to RTA. Yukichi zenke et al.^[20] in Japan, found in their study, mean age was 64.7 years with a standard deviation of ± 17.8 years in conventional group and compared conventional management with MIPO technique for volar locking plate fixation for distal radius fractures. The total mean age was 63.5 years the MIPO group was 62.1 ± 15.6 years. This may be attributed to the average life expectancy of Japanese people when compared to Indian people. In another study by Tamara D et al.^[21] the mean age group for ORIF was 51 years only and this reflects the increased life expectancy at Japan when compared to the western societies. This implies the existence of younger age population in our country, which when compared to the above two studies, it can be derived that these increased age groups reflect the country position in demographic cycles. Another study by Lozano-Calderon SA et al.^[26] which retrospectively compared percutaneous fixation of a volar plate and screws reported mean age of 55 years in percutaneous group and 51 years in ORIF volar plate group. However, the average age observed in the present study was comparable to the studies of Kilic A et al.^[25], Chung KC et al.^[27] and Anakwe E et al.^[28] who reported an average age of 45 years, 48.9 years and 48 years.

Present study reported 17.4 incidence of the complications. Contrary, Yukichi Zenke et al.^[20] reported only 3% incidence of complications included EPL tendon rupture, incomplete palsy of the superficial branch of median nerve and loosening of cortical screws in conventional ORIF group and 1% incidence of distal locking pin protrusion in MIPO group. Tamara D et al.^[21] reported one case of re-fracture and one case of deQuervain's tenosynovitis along with one case of extensor carpi ulnaris tendinitis both groups did not report any secondary osteoarthritis. Rohit Arora et al.^[24] reported significant more complications in the operative treatment group than the non-operative treatment group with the use of Fischer exact test with a P value of < 0.05 in their study. 36% from the operative treatment group had complications. Five

patients in their study had extensor tenosynovitis which they attributed to the screw penetration of dorso-radial cortex. Four patients developed flexor tendon tenosynovitis which necessitated implant removal; they reported one case of EPL tendon rupture with volar locking plate. A total number of 7 patients in the study including both operative and non-operative group had developed Type-1 CRPS. Marco Rizzo. Brain A. Katt. Joshua T et al.^[22] reported two cases of pin tract infection one case of finger stiffness in their external fixation/ pinning group. We encountered complications 4(8.7%) patients had CRPS, 2 patients had superficial wound infection, 1 patient of dorsal plating had dorsal tendon attrition, and single patient had an unusual complication of median nerve entrapment under surgical scar.

CONCLUSION

We concluded that prevention of the possible complications that can occur following treatment of a distal radius fracture must be the surgeon's foremost concern. Complications that do arise should be treated sooner to prevent any further long-term consequences. However, plate osteosynthesis provides successful results for the treatment of both extra articular and intra articular unstable fractures of distal radius. This method allows restoration of the anatomy, stable internal fixation, a decreased period of immobilisation and early return of wrist function. Also, this method is effective in the anatomic realignment, allows early joint motion, owing to its fixation strength. Volar approach provides both, access with minimal surgical trauma on distal radius and fixation with a better adaptation to surrounding tissues.

Funding Nil

Conflict of Interest Nil.

REFERENCES

1. Sarmento A, Zagorski J B, Sinclair WF. Functional racing of colle's fracture. A prospective study of immobilization in supination Vs pronation. *ClinOrthop*1980;146:175-83.
2. Kapandji IA. Internal fixation by double intra focal plate: functional outcome treatment of non-articular fractures of the lower end of radius *Ann chir*1976;30:903-08.
3. Rampoldi M, Marsico S. Complications of volar plating of distal radius fractures. *Acta Orthop Belg* 2007;73(06):714-719
4. Zenke Y, Sakai A, Oshige T, et al. Extensor pollicis longus tendon ruptures after the use of volar locking plates for distal radius fractures. *Hand Surg* 2013;18(02):169-73.
5. Asadollahi S, Keith PP. Flexor tendon injuries following plate fixation of distal radius fractures: a systematic review of the literature. *J Orthop Traumatol* 2013;14(04):227-34.
6. Zhao HL, Wang GB, Jia YQ, Zhu SC, Zhang FF, Liu HM. Comparison of risk of Carpal Tunnel syndrome in patients with distal radius fractures after 7 treatments. *Med Sci Monit* 2015;21:2837-44.
7. Fowler JR, Ilyas AM. Prospective evaluation of distal radius fractures treated with variable-angle volar locking plates. *J Hand Surg Am* 2013;38(11):2198-2203.
8. Arora R, Gabl M, Gschwentner M, Deml C, Krappinger D, Lutz M. A comparative study of clinical and radiologic

- outcomes of unstable Colles type distal radius fractures in patients older than 70 years: nonoperative treatment versus volar locking plating. *J Orthop Trauma* 2009;23(04):237–42.
9. Bales JG, Stern PJ. Treatment strategies of distal radius fractures. *Hand Clin* 2012;28(02):177–84.
 10. Roh YH, Lee BK, Baek JR, Noh JH, Gong HS, Baek GH. A randomized comparison of volar plate and external fixation for intra-articular distal radius fractures. *J Hand Surg Am* 2015;40(01):34–41
 11. Schnependahl J, Windolf J, Kaufmann RA. Distal radius fractures: current concepts. *J Hand Surg Am* 2012;37(08):1718–25.
 12. Chung KC, Shauver MJ, Birkmeyer JD. Trends in the United States in the treatment of distal radial fractures in the elderly. *J Bone Joint Surg Am* 2009;91(08):1868–73.
 13. Hakimi M, Jungbluth P, Windolf J, Wild M. Functional results and complications following locking palmar plating on the distal radius: a retrospective study. *J Hand Surg Eur Vol* 2010;35(04): 283–88.
 14. Jie W, Tu-Bao Y, Wei L, Jia-Bi Q, Fan-Jing K. Complications following dorsal versus volar plate fixation of distal radius fracture: A meta-analysis. *Journal of International Medical Research* 41(2) doi.10.1177/0300060513476438.
 15. Ng CY, McQueen MM. What are the radiological predictors of functional outcome following fractures of the distal radius? *J Bone Joint Surg Br* 2011;93(B):145–50.
 16. Arora R, Lutz M, Deml C et al. A Prospective randomized trial comparing nonoperative treatment with volar locking plate fixation for displaced and unstable distal radial fractures in patients sixty-five years of age and older. *J Bone Jt Surg Am* 2011;93:2146-2153.
 17. Ng CY, McQueen MM. What are the radiological predictors of functional outcome following fractures of the distal radius? *J Bone Joint Surg Br* 2011;93(B):145–150.
 18. Schmitt R, Pommersberger K, Karpale Funktion, Morphometrie. In: Schmitt R, Lanz U (eds) *Bildgebende Diagnostik der Hand*. 3rd edn. Thieme, Germany 2014:184–97
 19. Soong M, Earp BE, Bishop G et al. Volar locking plate implant prominence and flexor tendon rupture. *J Bone Jt Surg Ser A* 2011;93:328–35.
 20. Yukichi Zenke, Akinori Sakai, Toshihisa Oshige, Shiro Moritani, Yoshifumi Fuse, Takashi Maehara et al. Clinical Results of Volar Locking Plate for Distal Radius Fractures: Conventional versus Minimally Invasive Plate Osteosynthesis *J Ortho Trauma* 2011;25(7).
 21. Tamara D Rozental, Philip E Blazar, Orrin I Franko, Aron T Chacko, Brandon Earp, Charles S. Day: Functional Outcomes for Unstable Distal Radial Fractures Treated with Open Reduction and Internal Fixation or Closed Reduction and Percutaneous Fixation. A Prospective Randomized Trial. *J Bone Joint Surg Am* 2009;91:1837-1846.
 22. Marco Rizzo, Brian A Katt, Joshua T Carothers. Comparison of Locked Volar Plating Versus Pinning and External Fixation in the Treatment of Unstable Intra-articular Distal Radius Fractures. *HAND* 2008;3:111–117.
 23. K. Egol, M. Walsh, N. Tejwani, T. Mc Laurin, C. Wynn, N. Paksima. Bridging external fixation and supplementary Kirschner-wire fixation versus volar locked plating for unstable fractures of the distal radius A RANDOMISED, PROSPECTIVE TRIAL. *J Bone Joint Surg [Br]* 2008;90-B:1214- 21
 24. Arora R, Lutz M, Hennerbichler A, Krappinger D, Espen D, Gabl M. Complications following internal fixation of unstable distal radius fracture with a palmar locking-plate. *J Orthop Trauma* 2007;21(5):316-22.
 25. Kilic A, Kabukcuoglu Y, Ozkaya U, Gul M, Sokucu M, Ozdogan U. Volar locking plate fixation of unstable distal radius fractures. *Acta Orthop Traumatol Turc* 2009;43(4):303-8.
 26. Lozano-Calderon SA, Doomberg JN, Ring D. Retrospective comparison of percutaneous fixation and volar internal fixation of distal radius fractures. *Hand (N Y)*. 2008;3(2):102-10
 27. Chung Kevin C, Watt Andrws, Kotsis Sandra, Margaliot ZVI, Hase Steven, Kim H Myra. Treatment of unstable distal radius fractures with volar locking compression plate. *The J Bone & Joint Surg* 2006;88- A (12):2687- 94
 28. Anakwe RE, Khan LAK, Cook RE, Mc Eachan JE. Locked volar plating for complex distal radius fractures: Patient reported outcomes and satisfaction *J Orthop Surg Res* 2010;5:51.